

# CASE STUDY

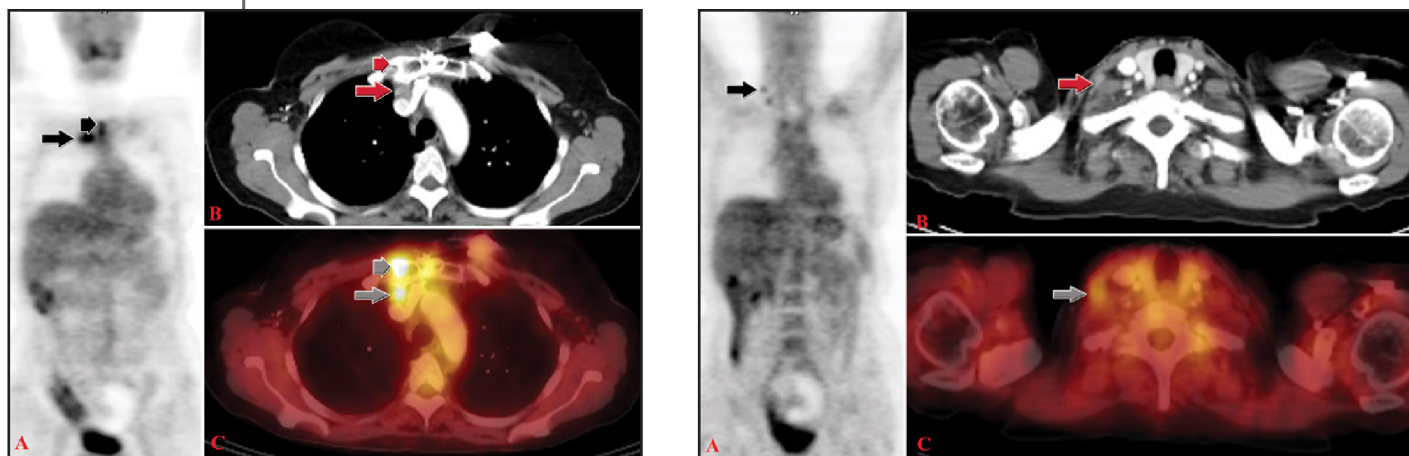
## BREAST

### HISTORY

55-year-old woman with recurrent breast cancer referred for PET/CT evaluation prior to radiation therapy. A CT scan performed 3 weeks before PET/CT was performed, showed a parasternal mass. The remainder of the CT scan was negative.

### PET/CT FINDINGS

Intense FDG uptake in the parasternal mass (left) with apparent sternal invasion. Additionally, there are two small foci of mild to moderate FDG activity in the right supraclavicular area corresponding to non-enlarged lymph nodes (right).



### TREATMENT / FOLLOW UP

Follow up PET/CT after radiation therapy showed marked interval decrease in tumor involvement in the sternum and anterior mediastinum after radiation therapy. No abnormal areas of FDG activity are present.

### DISCUSSION

This patient was referred for PET/CT after being diagnosed with recurrence of breast cancer in her anterior mediastinum by CT. Her radiation oncologist ordered the exam prior to radiation therapy to evaluate for extent of disease and for whole body evaluation prior to therapy. Her PET/CT identified two unsuspected small normal-sized hypermetabolic lymph nodes in the right supraclavicular area. Her radiation therapy plan was revised to include the right supraclavicular area.

# CASE STUDY

## BREAST

Her follow up PET/CT (below) after radiation therapy showed a very good response to therapy with no residual uptake in the parasternal mass or in the right supraclavicular area.

